

### CLINICAL PRESENTATION

Young male presents with pleuritic chest pain & shortness of breath.

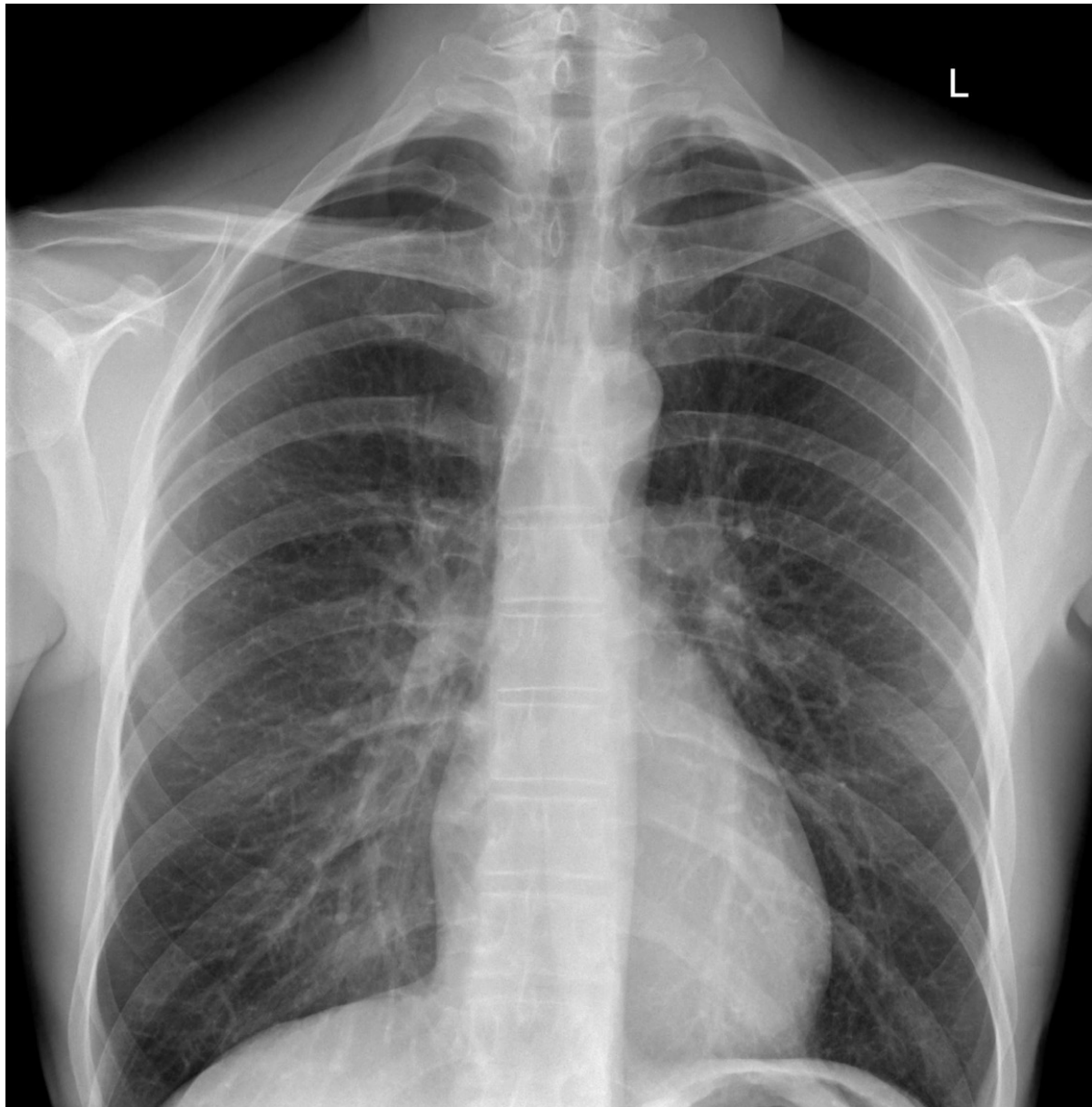
What are the findings on the chest x-ray?

What features would indicate a complication of this condition?

What features would you look for in a supine patient?

### IMAGES

PA CHEST X-RAY



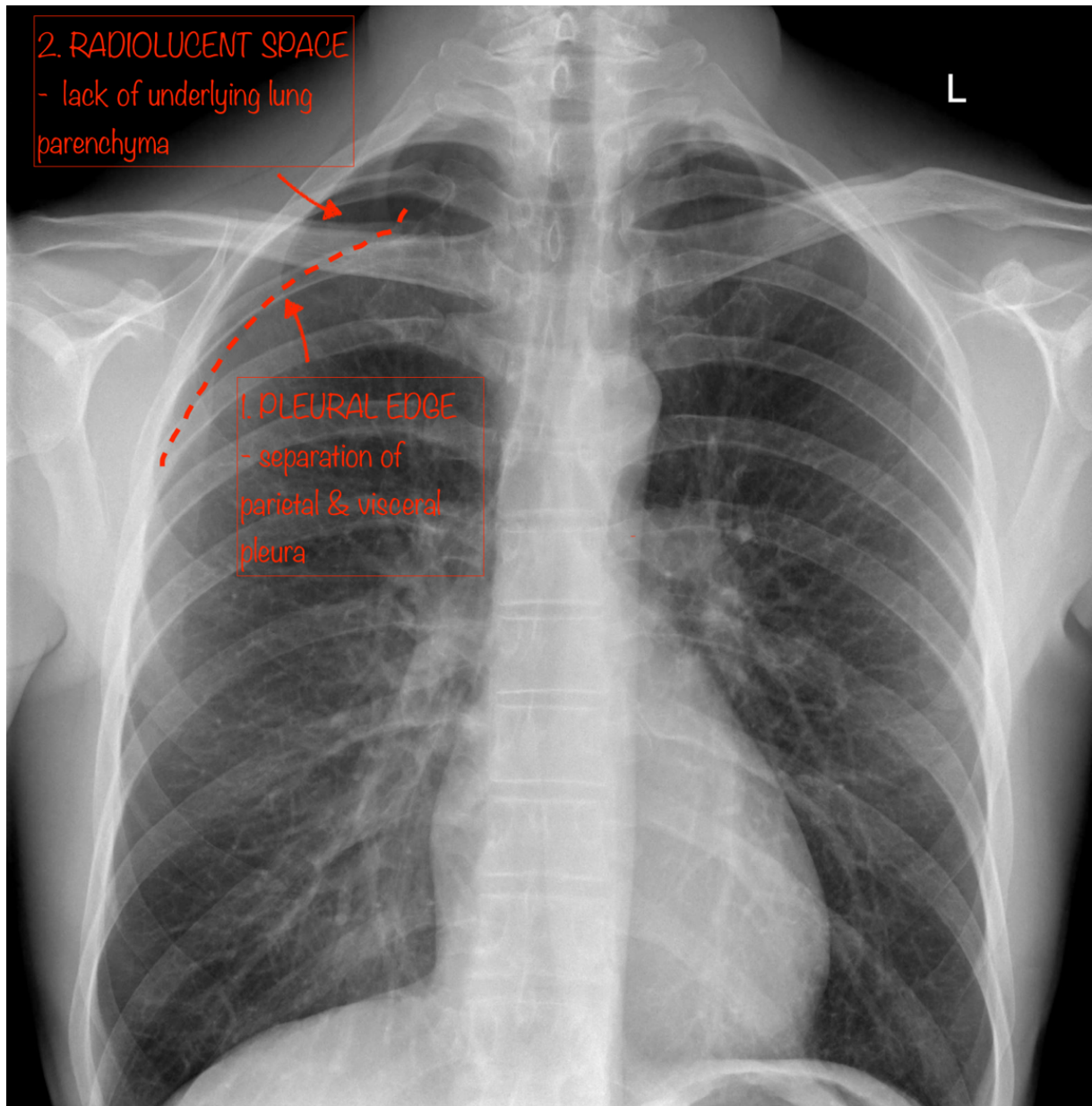
Case courtesy of Dr. M. Imran Khan

Radiopaedia.org <https://radiopaedia.org/>

From the case <https://radiopaedia.org/cases/65158> rID: 65158

## ANNOTATED IMAGES - PNEUMOTHORAX

PA CHEST X-RAY – CASE

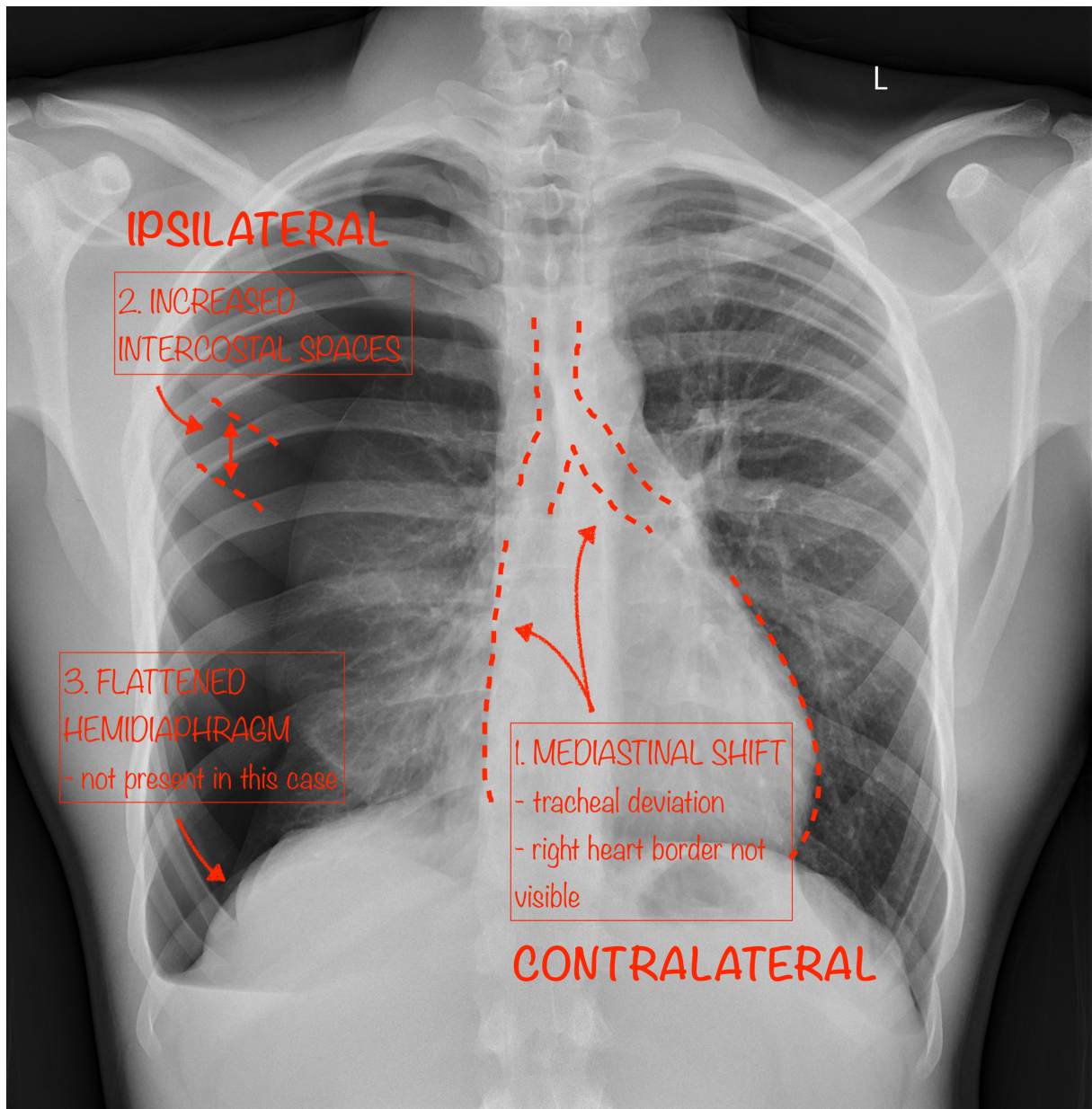


Case courtesy of Dr. M. Imran Khan

Radiopaedia.org <https://radiopaedia.org/>

From the case <https://radiopaedia.org/cases/65158> rID: 65158

PA CHEST X-RAY – FEATURES OF A TENSION PNEUMOTHORAX



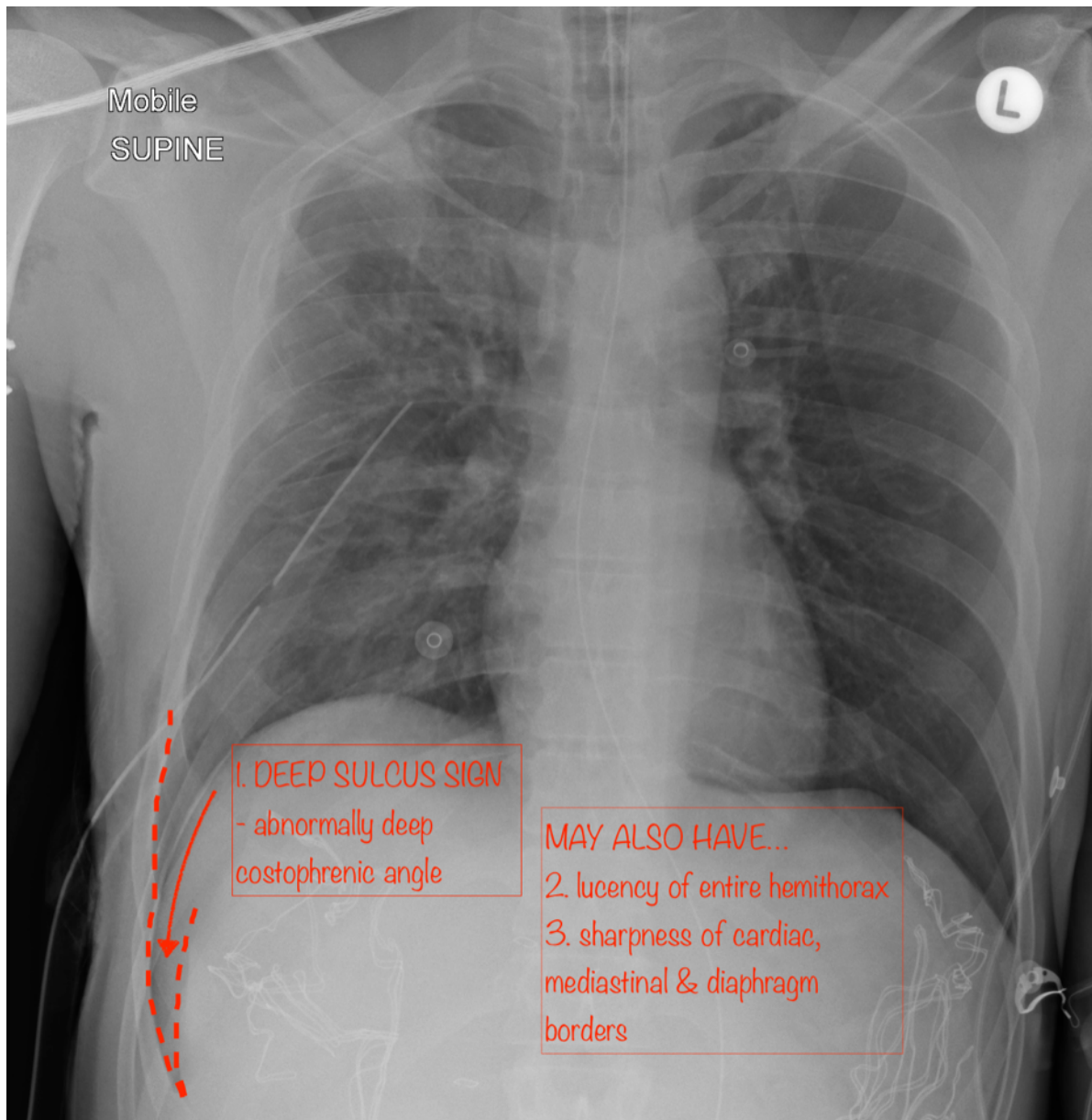
Case courtesy of Dr Ana Brusic

Radiopaedia.org <https://radiopaedia.org/>

From the case <https://radiopaedia.org/cases/60551> rID: 60551



## MOBILE SUPINE CHEST X-RAY – HOW TO IDENTIFY A PNEUMOTHORAX IN A SUPINE PATIENT



Case courtesy of Dr Andrew Dixon

Radiopaedia.org <https://radiopaedia.org/>

From the case <https://radiopaedia.org/cases/55473> rID: 55473

### RESOURCES

- <https://radiopaedia.org/articles/pneumothorax?lang=us>
- <https://radiopaedia.org/articles/tension-pneumothorax?lang=us>
- <https://radiopaedia.org/articles/pneumothorax-in-supine-projection?lang=us>
- <https://radiologyassistant.nl/chest/chest-x-ray-basic-interpretation#pleura-pneumothorax>
- <https://oxfordmedicine-com.ezp.lib.unimelb.edu.au/view/10.1093/med/9780199216369.001.0001/med-9780199216369-chapter-0004#med-9780199216369-div2-005016>