

CLINICAL PRESENTATION

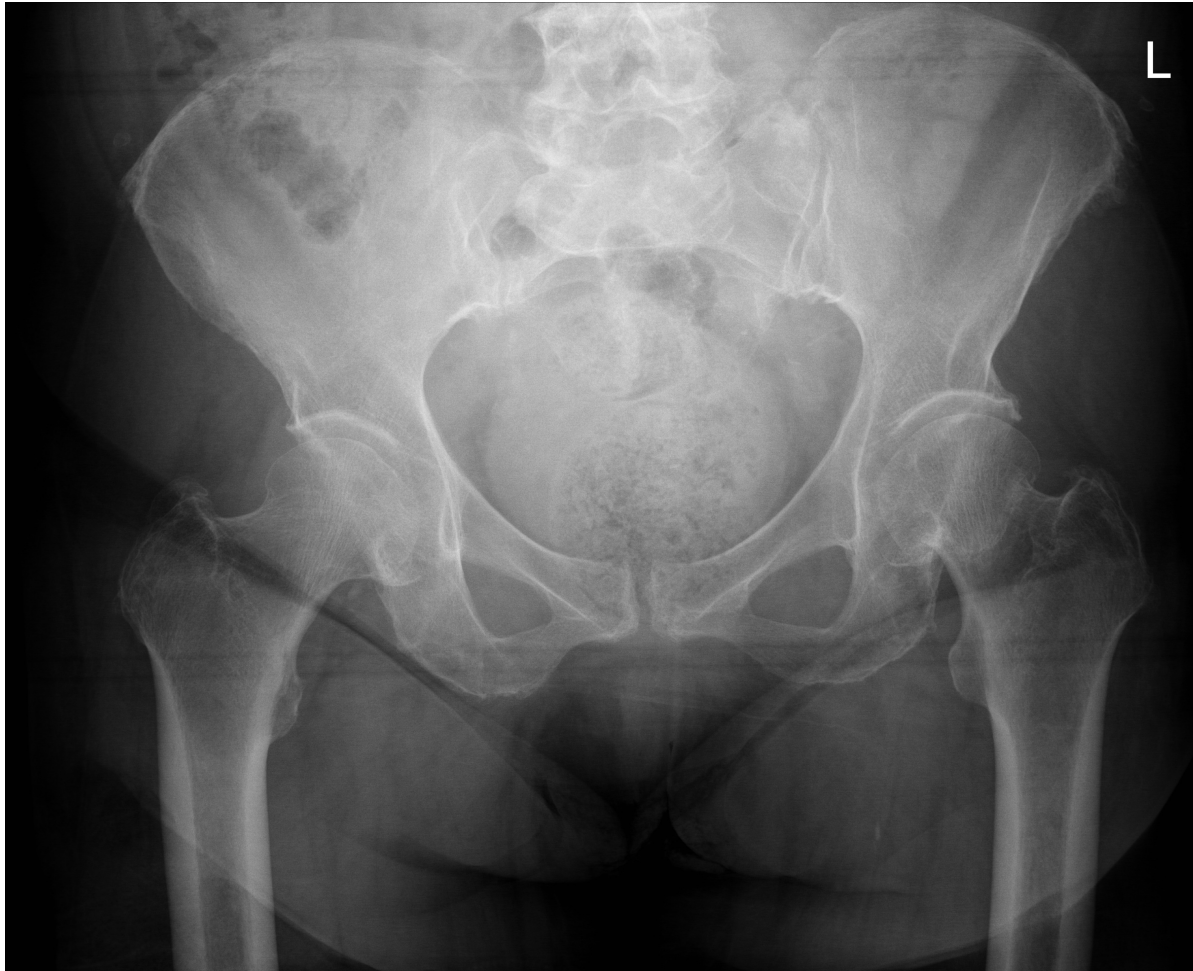82 year old female presents with groin pain after a fall from standing height.

What are the findings on the pelvic x-ray?

What are the features of complications you would look for?

IMAGES

PELVIC X-RAY



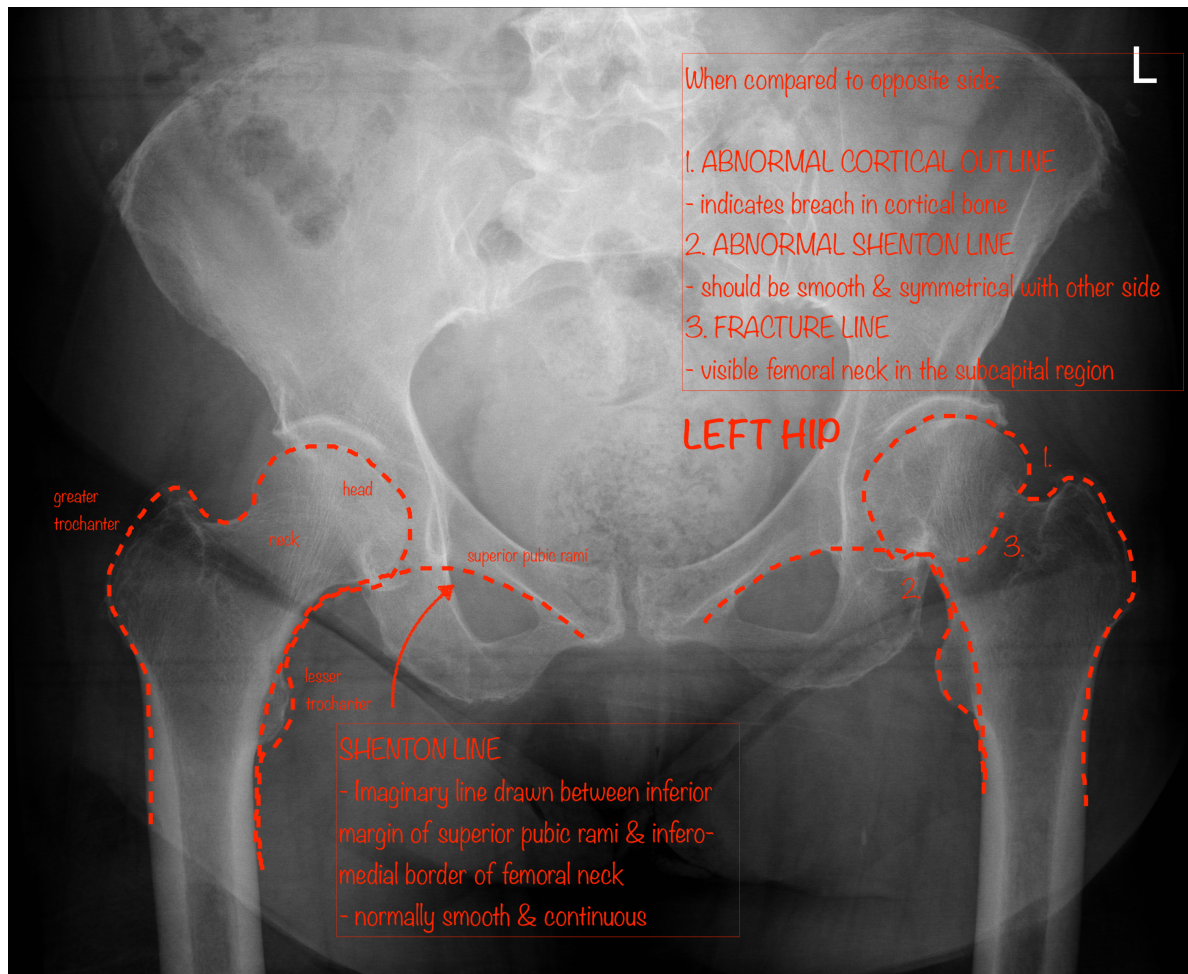
Case courtesy of Dr Mark Holland

Radiopaedia.org <https://radiopaedia.org/>

From the case <https://radiopaedia.org/cases/22056> rID: 22056

ANNOTATED IMAGES – FRACTURED NECK OF FEMUR

ANNOTATED PELVIC X-RAY # NOF



Case courtesy of Dr Mark Holland

Radiopaedia.org <https://radiopaedia.org/>

From the case <https://radiopaedia.org/cases/22056> rID: 22056

RESOURCES

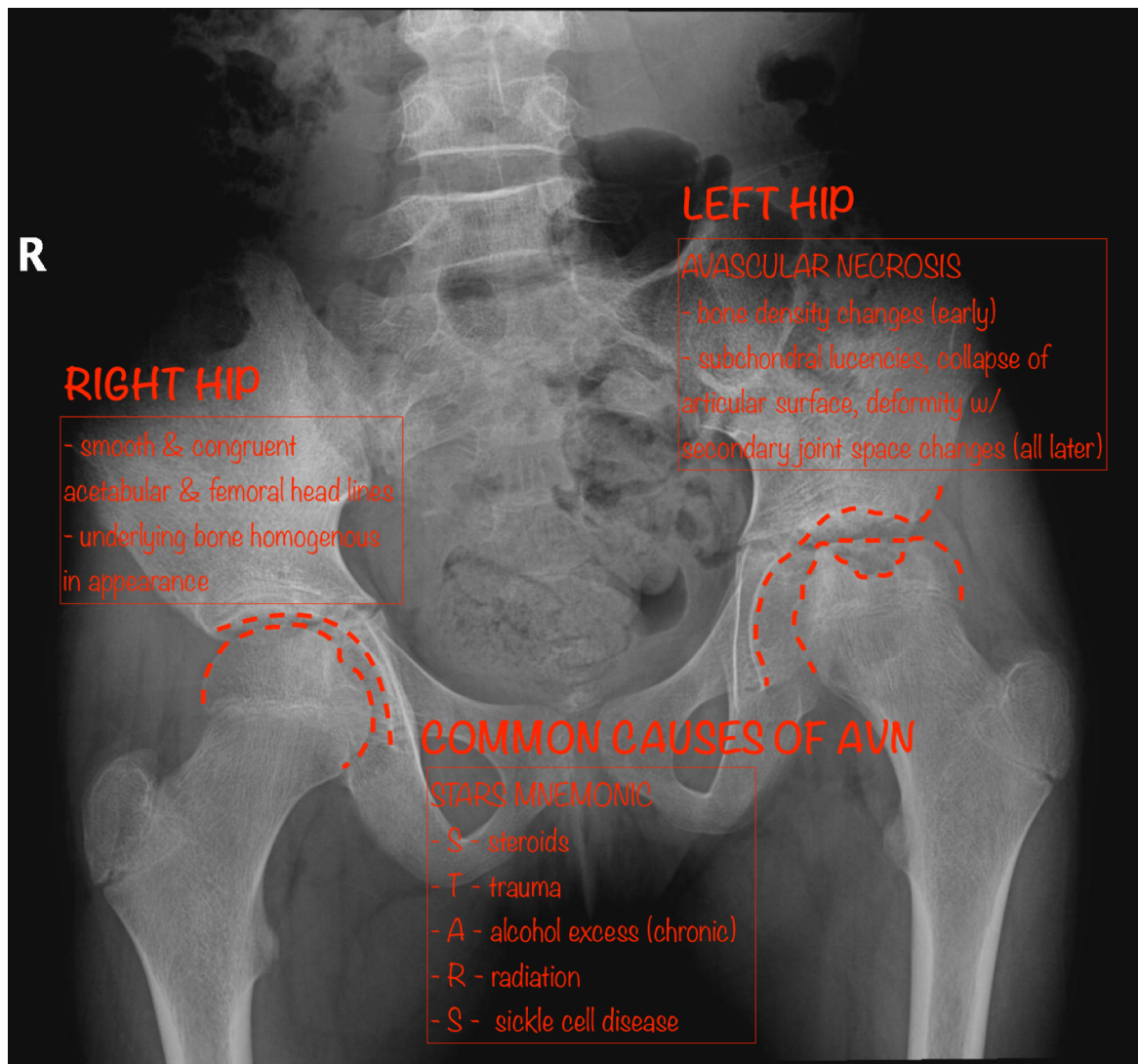
How to assess a pelvic radiograph:

<https://radiopaedia.org/articles/pelvic-radiograph-an-approach>

How to classify proximal femoral fractures:

<https://radiopaedia.org/cases/proximal-femoral-fractures-illustration?lang=us>

AVN ON PELVIC X-RAY

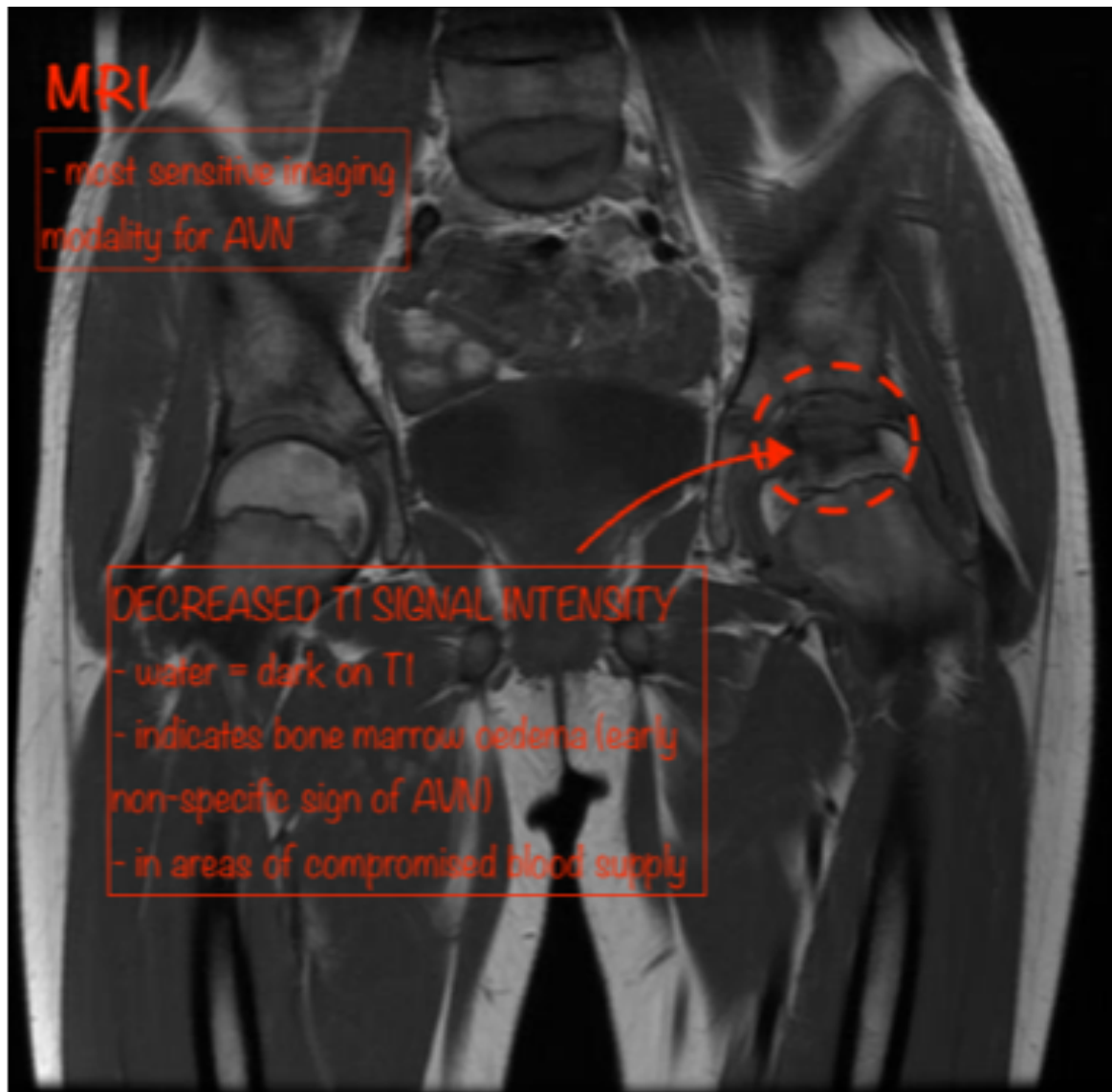


Case courtesy of Dr Hani Salam

Radiopaedia.org <https://radiopaedia.org/>

From the case <https://radiopaedia.org/cases/29563> rID: 29563

AVN ON MRI – CORONAL T1-WEIGHTED IMAGE

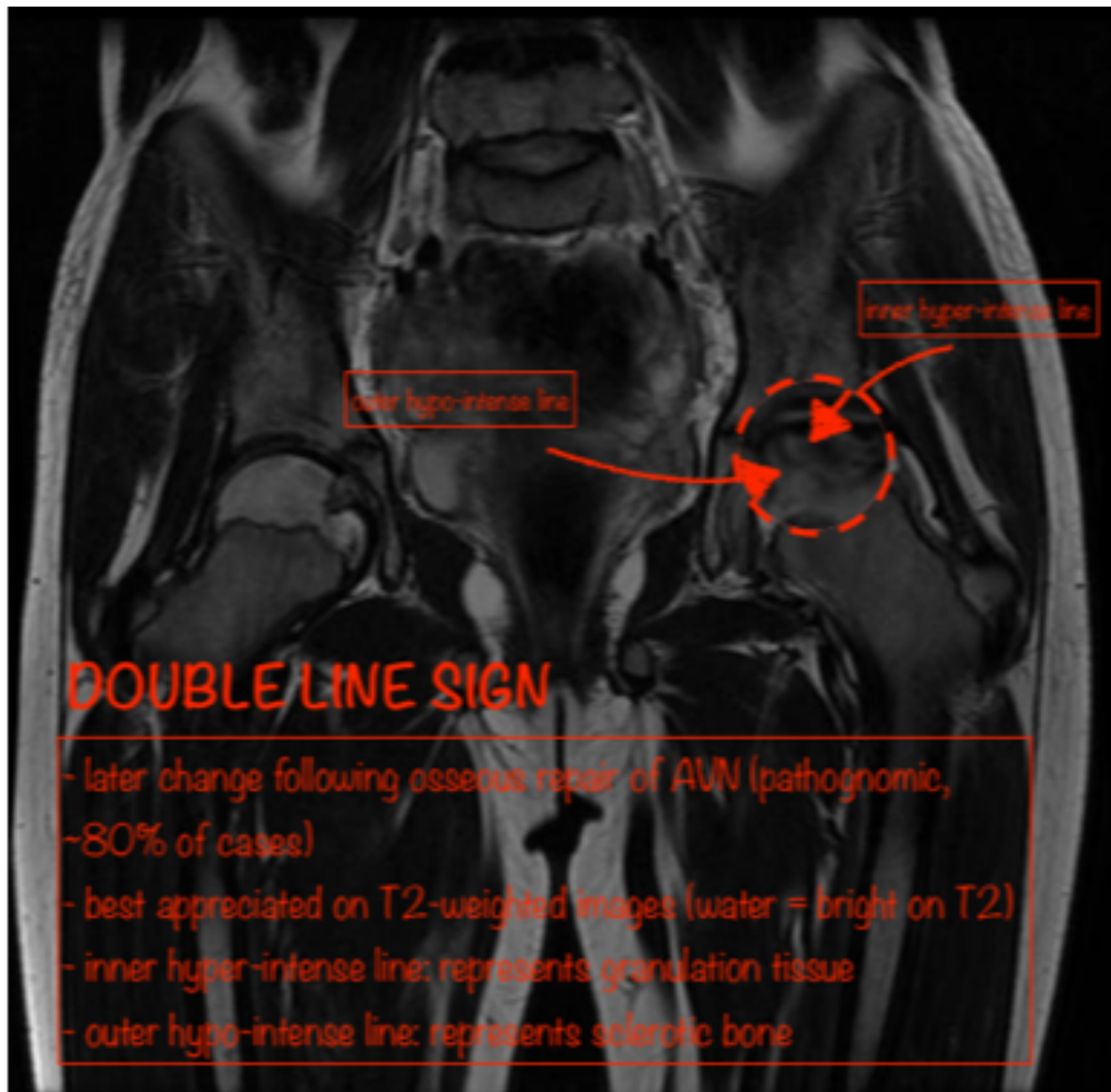


Case courtesy of Dr Hani Salam

Radiopaedia.org <https://radiopaedia.org/>

From the case <https://radiopaedia.org/cases/29563> rID: 29563

AVN ON MRI – CORONAL T1-WEIGHTED IMAGE



Case courtesy of Dr Hani Salam

Radiopaedia.org <https://radiopaedia.org/>

From the case <https://radiopaedia.org/cases/29563> rID: 29563

RESOURCES

- <https://radiopaedia.org/articles/proximal-femoral-fractures?lang=us>
- <https://radiopaedia.org/articles/femoral-neck-fracture?lang=us>
- <https://radiopaedia.org/articles/pelvic-radiograph-an-approach>
- <https://radiopaedia.org/articles/avascular-necrosis-of-the-hip?lang=us>
- <https://radiopaedia.org/articles/avascular-necrosis-causes-mnemonic>
- <https://radiopaedia.org/articles/double-line-sign?lang=us>
- <https://oxfordmedicine-com.ezp.lib.unimelb.edu.au/view/10.1093/med/9780199216369.001.0001/med-9780199216369-chapter-0019#med-9780199216369-div1-025021>